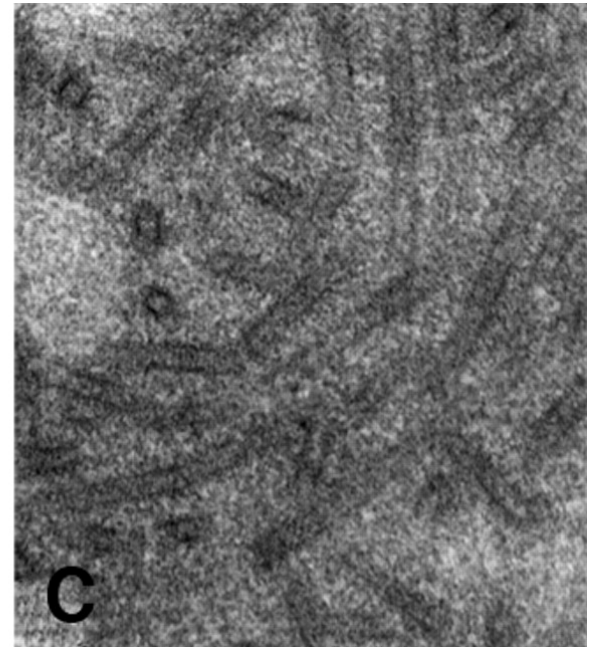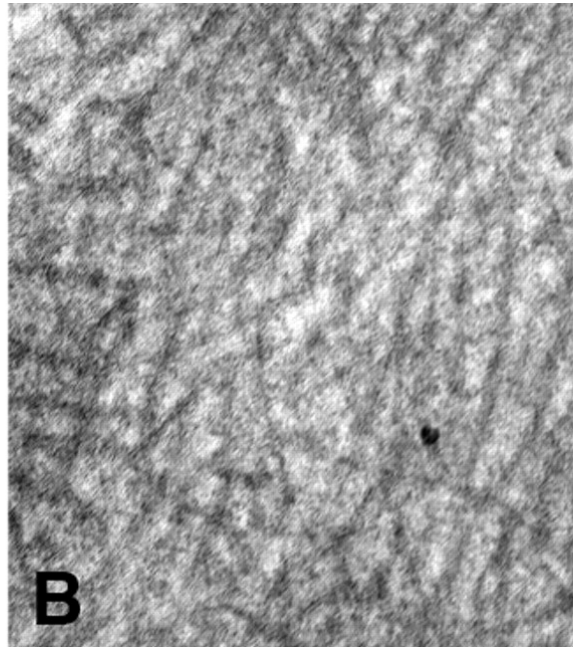
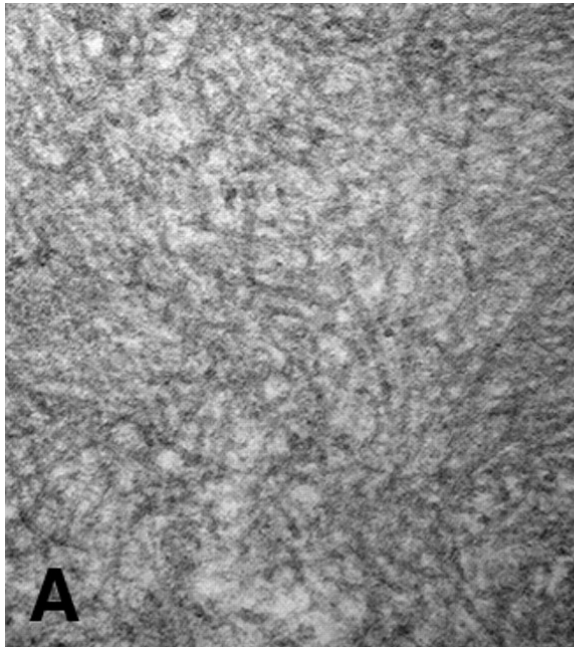


Ultrastructural features of the fibrils of amyloid (A), fibrillary glomerulonephritis (B), and microtubules of immunotactoid glomerulopathy (C).



**Charles E. Alpers, and Jolanta Kowalewska JASN
2008;19:34-37**

